



Neural substrates of autobiographical memory retrieval in unilateral temporal lobe epilepsy: an fMRI study



D. R. Addis^{1,2}, M. Moscovitch¹, A. P. Crawley², and M. P. McAndrews^{1,2}

¹ Department of Psychology, University of Toronto, Toronto, Ontario; ² Toronto Western Research Institute, University Health Network, Toronto, Ontario

Introduction

- Recent neuroimaging studies of autobiographical memory (AM) retrieval have consistently reported the activation of an AM network that includes hippocampus, parahippocampus, posterior cingulate, precuneus, and medial frontal regions¹.
- AM retrieval appears to activate preferentially the hippocampus (HC) as part of this network¹. This is consistent with lesion evidence that HC damage is associated with AM deficits².
- To date, only one functional imaging study has investigated AM retrieval in a patient with bilateral HC damage. Maguire et al.³ report activity in residual HC tissue, as well as recruitment of regions not significantly active in control participants.
- Patients with temporal lobe epilepsy (TLE) provide an opportunity to investigate the impact of unilateral hippocampal damage on the neural substrates of AM retrieval.
- We conducted an event-related fMRI study, comparing neural activity associated with AM retrieval in controls and TLE patients.

Methods

Participants

- 14 controls (6 male)
- 9 left TLE (5 male)
- 6 right TLE (4 male)

Autobiographical Interview (AI)⁴

- Recalled 2 recent and 2 remote AMs
- Transcribed AMs segmented into details
- Number of details **internal** to the central episodic event used as covariate in imaging analyses to statistically match groups

Pre-Scan Interview

- Participants retrieved 20 AMs and devised AM "titles" to be later used as cues
- Each AM rated on a five-point scale for level of detail and personal significance

Scanning Protocol

- AM task**
 - Retrieve** AM in response to visually presented AM title (6 s)
 - Rate** AM for either level of detail or personal significance (4 s)
 - Rest** (6 s)
- Control task: Sentence completion**
 - Complete** a visually presented sentence (4 s)
 - Rate** for task difficulty (4 s)
 - Rest** (8 s)
- Control task: Size discrimination**
 - Decide** largest of two named objects (4 s)
 - Rate** for task difficulty (4 s)
 - Rest** (8 s)
- Ten of each task randomly presented during each run; participants completed two runs
- Post-scan interview to verify retrieval success

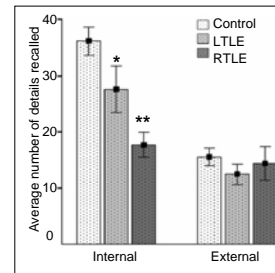
Analyses

- SPM2 random-effects analyses
- 1. AM – control tasks for each group
- 2. Group contrasts of AM – control tasks with AI internal detail as covariate

Results

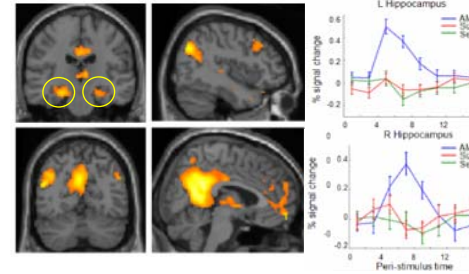
Autobiographical Interview

- LTLE and RTLE recalled significantly fewer internal details than control participants.
- No significant differences in number of external details recalled



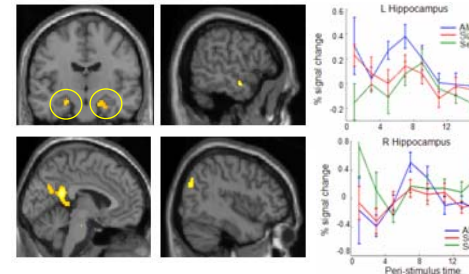
Controls: AM retrieval – Control tasks

- AM retrieval resulted in activation of AM network including bilateral HC ($p < .05$, corr).



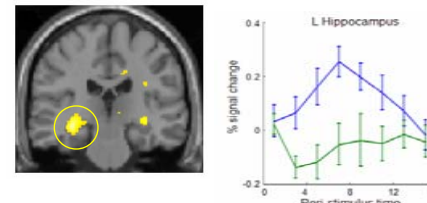
LTLE: AM retrieval – Control tasks

- AM retrieval resulted in weak activation of some AM network structures, incl. bilateral HC ($p < .001$, uncorr).



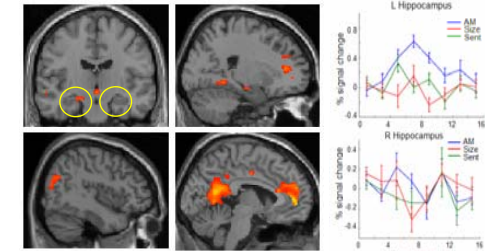
Controls vs. LTLE: AM retrieval – control tasks

- Controls show significantly more activity throughout the AM network, including bilateral HC ($p < .001$, uncorr)
- HC ROI analysis: LHC difference significant ($p < .05$, corr)



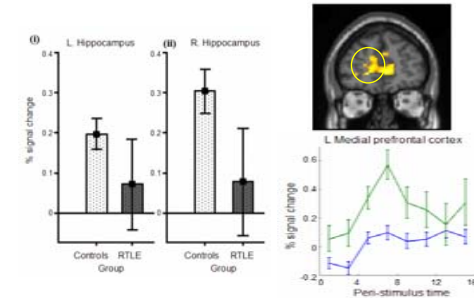
RTLE: AM retrieval – Control tasks

- AM retrieval resulted in weak activation of AM network structures, including the intact left HC ($p < .001$, uncorr).



Controls vs. RTLE: AM retrieval – control tasks

- RTLE show significantly more activity in some AM network structures (e.g., left medial PFC) & recruit some additional regions (e.g., bilateral lingual gyrus; $p < .001$, uncorr)
- HC ROI analysis: No significant differences; RTLE high variability



Conclusions

- These results indicate alterations in the neural network supporting AM retrieval in the context of unilateral HC damage.
- LTLE patients exhibited an overall decrease of activity across the AM network, including bilateral HC.
- In contrast, RTLE patients did not differ significantly from controls with respect to HC activity. RTLE patients engaged some AM network structures more than controls, and recruited additional regions, suggesting possible compensatory mechanisms.
- This pattern is consistent with the hypothesis⁵ that LHC plays a leading role in AM retrieval, perhaps initiating engagement of the AM network. Thus when the left side is dysfunctional, the remainder of the network is downregulated, even when patients can retrieve AMs.

REFERENCES

- ¹ Maguire, E.A., & Mummery, C.J. (1999). Differential modulation of a common memory network revealed by PET. *Hippocampus*, 9, 54 – 61
- ² Nadel, L., & Moscovitch, M. (1997). Memory consolidation, retrograde amnesia and the hippocampal complex. *Current Opinion in Neurobiology*, 7, 217 – 227.
- ³ Maguire, E.A. et al. (2001). The effects of bilateral hippocampal damage on fMRI regional activations and interactions during memory retrieval. *Brain*, 124, 1156 – 1170.
- ⁴ Levine et al. (2002). Aging and autobiographical memory: dissociating episodic from semantic retrieval. *Psychology and Aging*, 17, 677 – 689.
- ⁵ Maguire & Frith (2003). Aging affects the engagement of the hippocampus during autobiographical memory retrieval. *Brain*, 126, 1511 – 1523.